



Derin Ven Trombozu Pulmoner Emboli EKOS

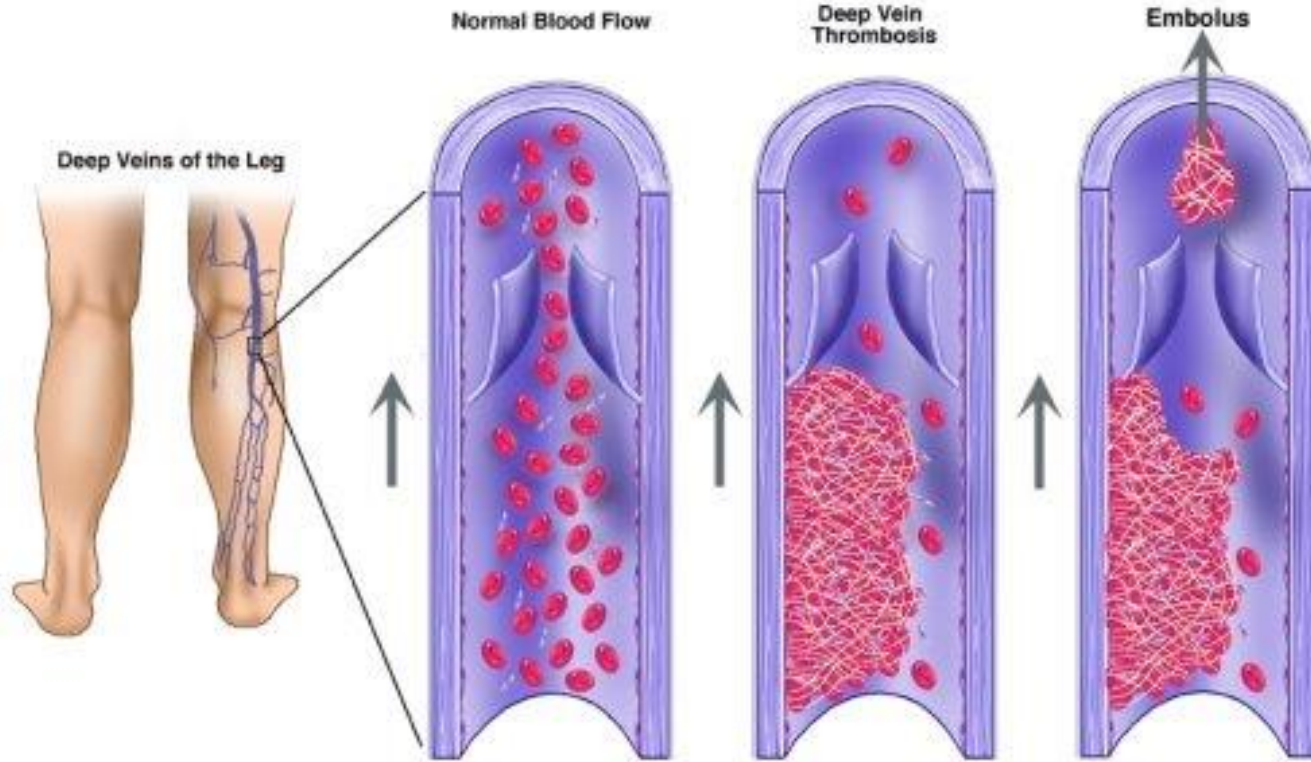
MEDICALPARK

Prof. Dr. Hüseyin Okutan

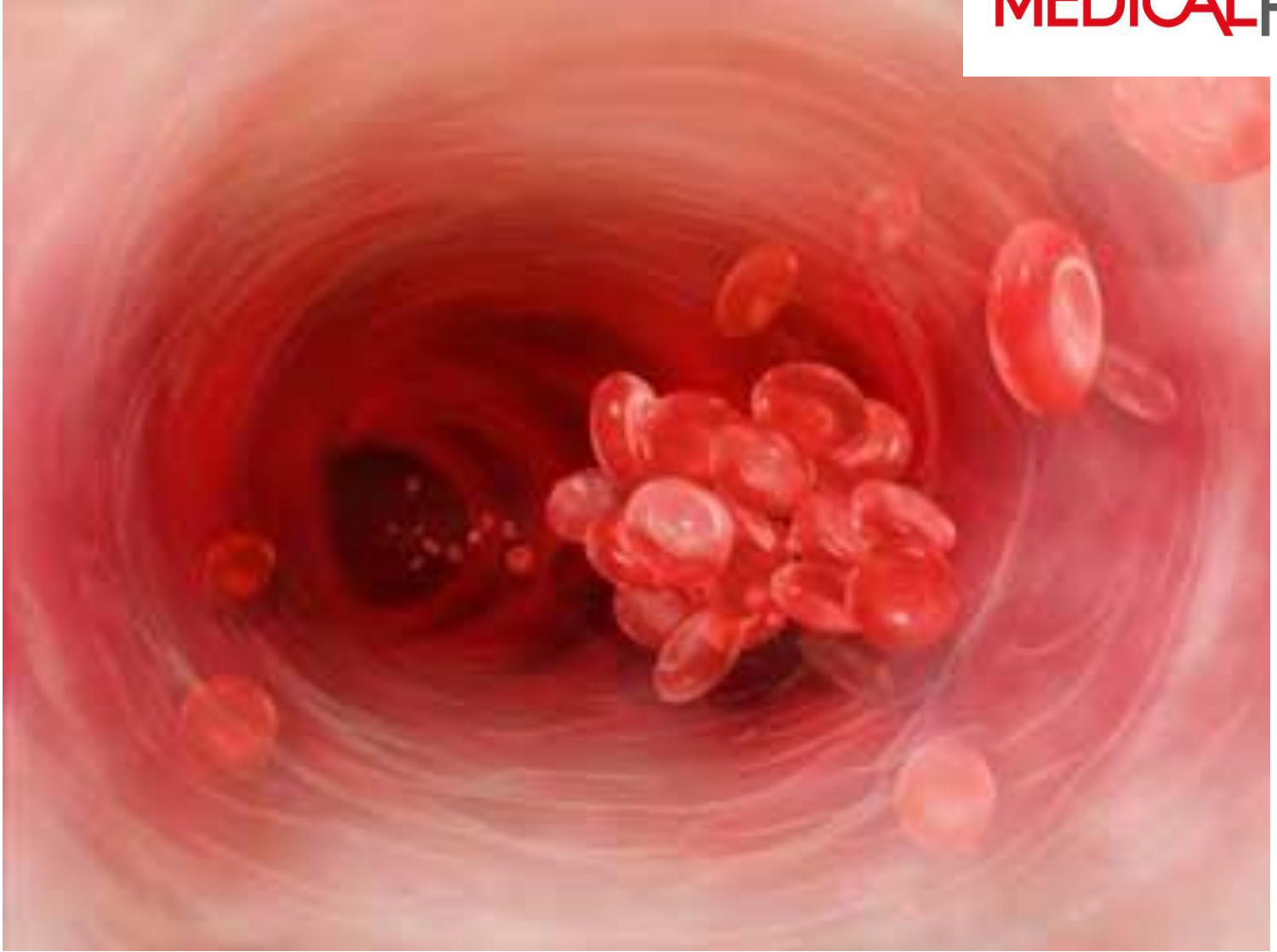


Antalya Kalp Hastanesi
Kalp ve Damar Cerrahisi Kliniđi

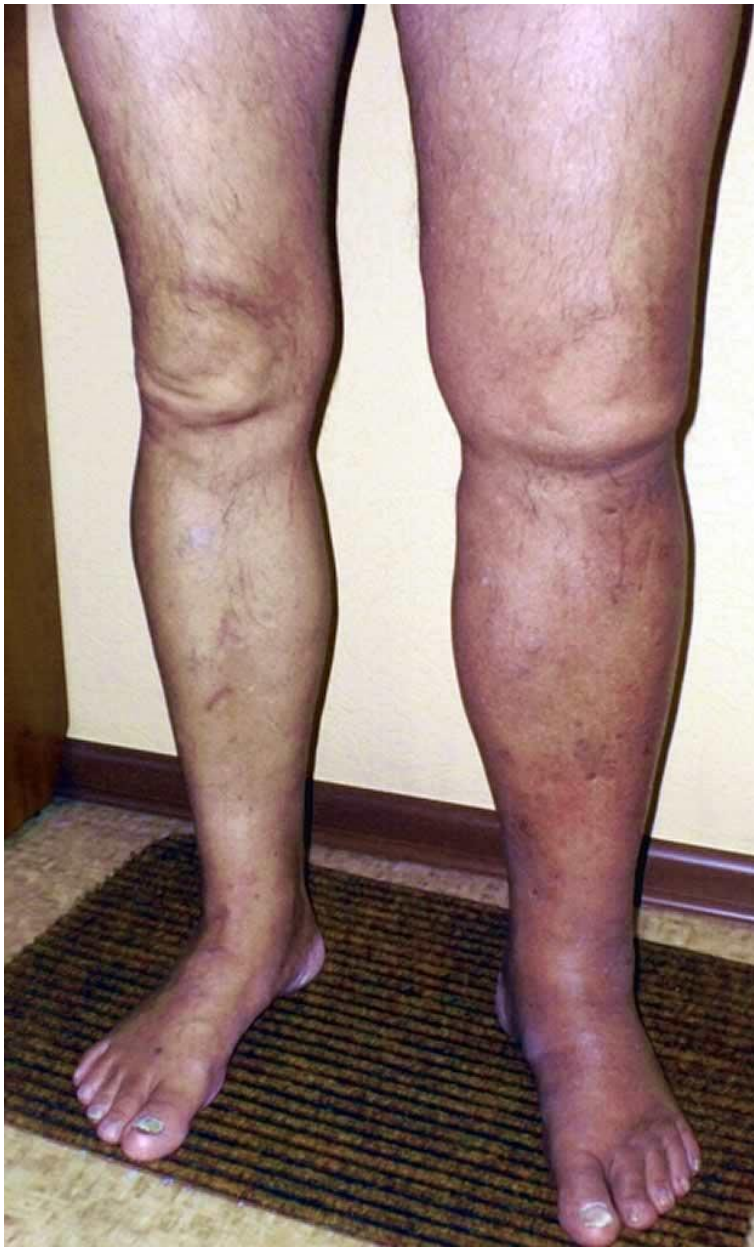Derin Ven Trombozu



Antalya Kalp Hastanesi
Kalp ve Damar Cerrahisi Kliniği

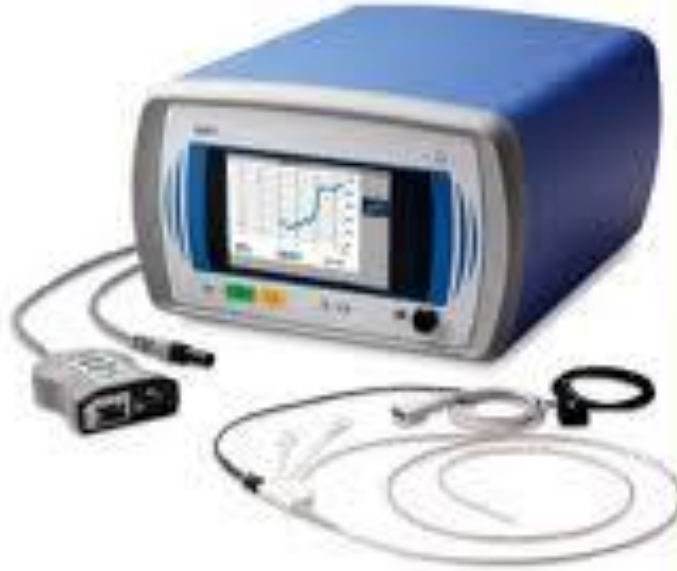

Antalya Kalp Hastanesi
Kalp ve Damar Cerrahisi Kliniđi

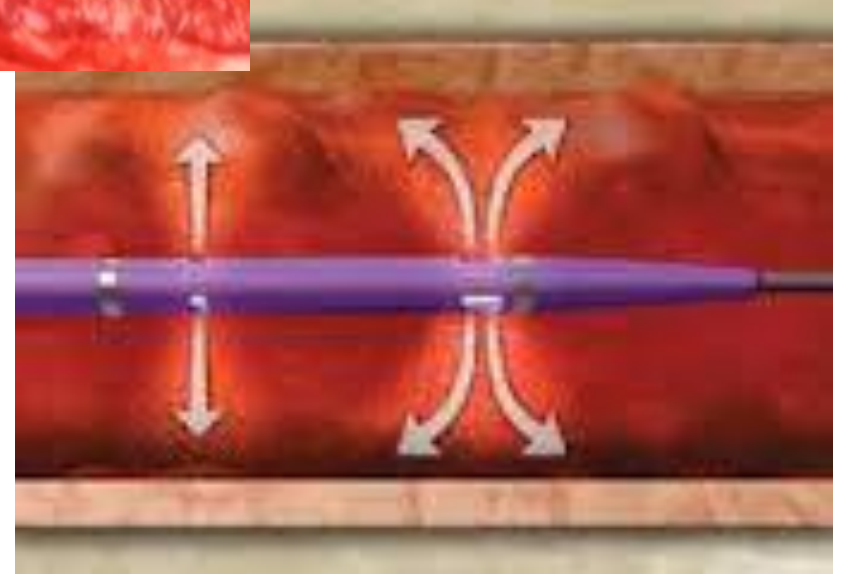
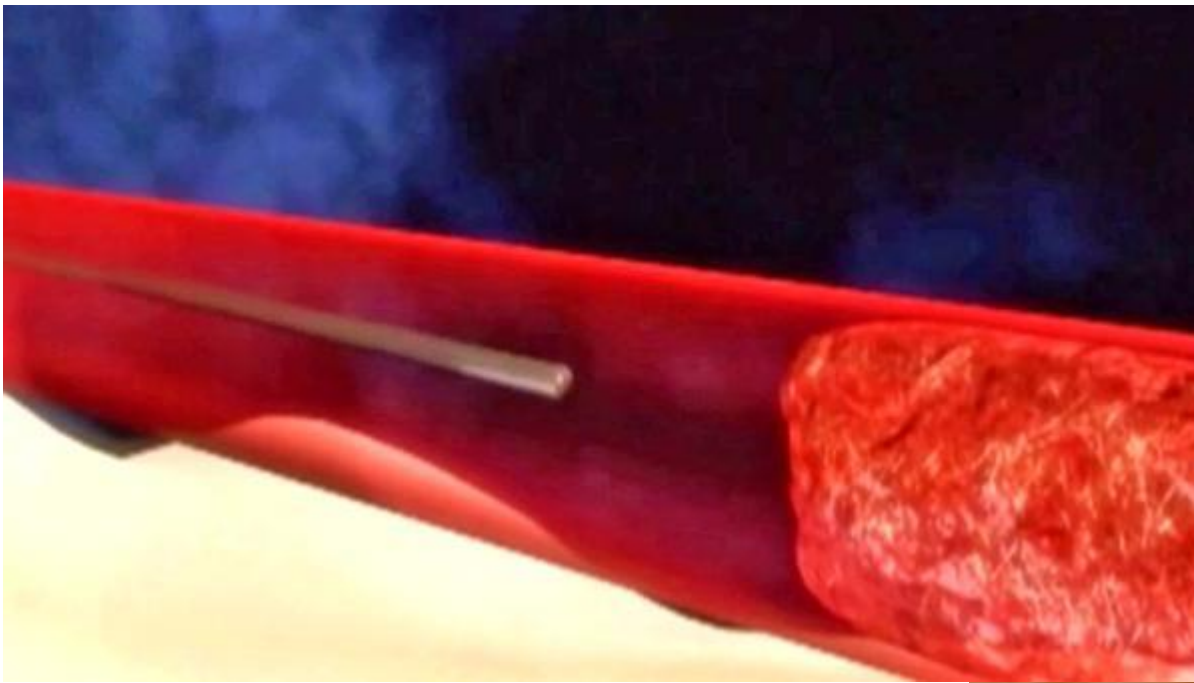


Antalya Kalp Hastanesi
Kalp ve Damar Cerrahisi Kliniđi


echos



Antalya Kalp Hastanesi
Kalp ve Damar Cerrahisi Kliniđi



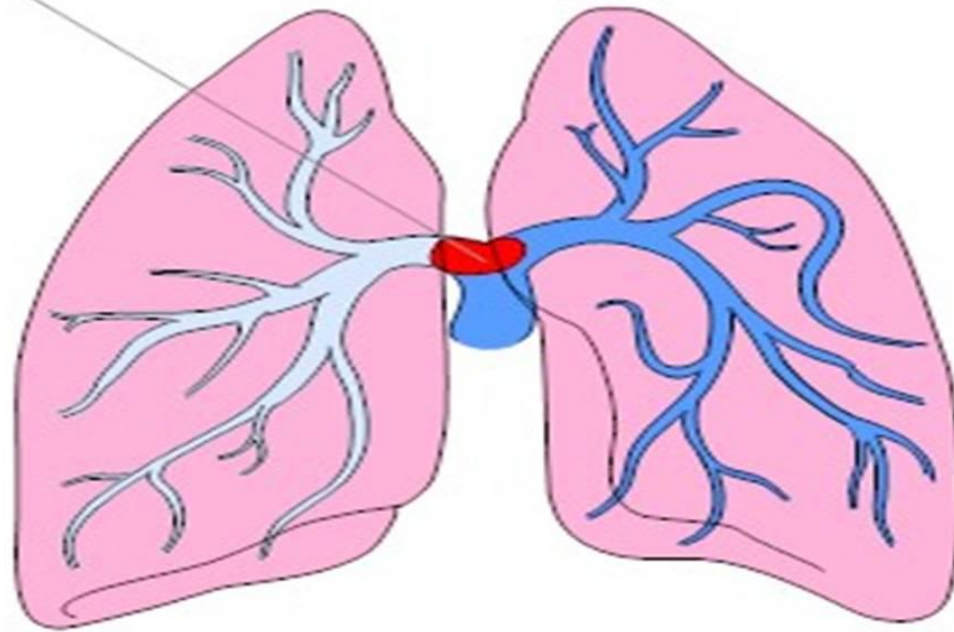
Antalya Kalp Hastanesi
Kalp ve Damar Cerrahisi Kliniđi



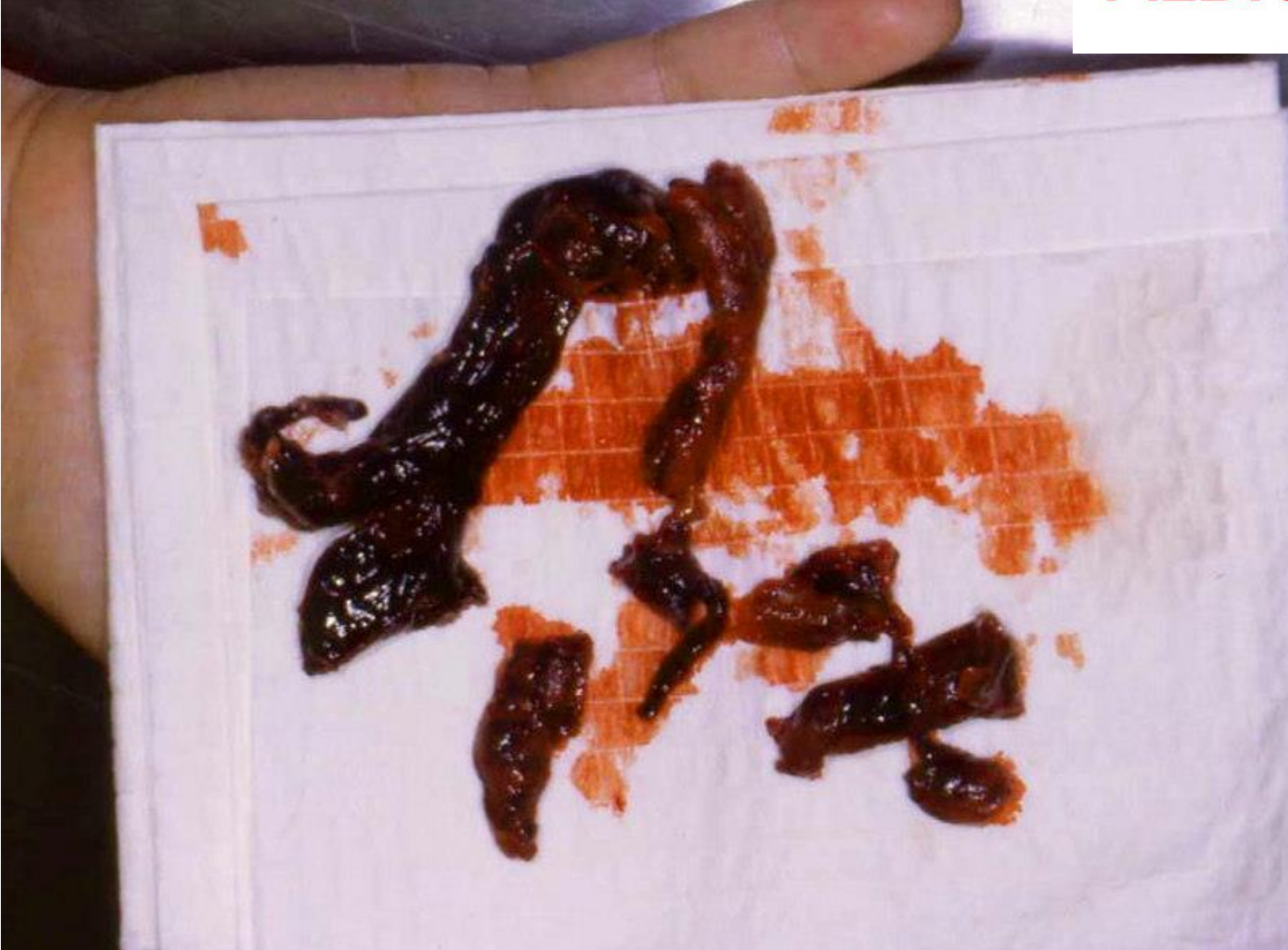Antalya Kalp Hastanesi
Kalp ve Damar Cerrahisi Kliniđi

Pulmoner Emboli

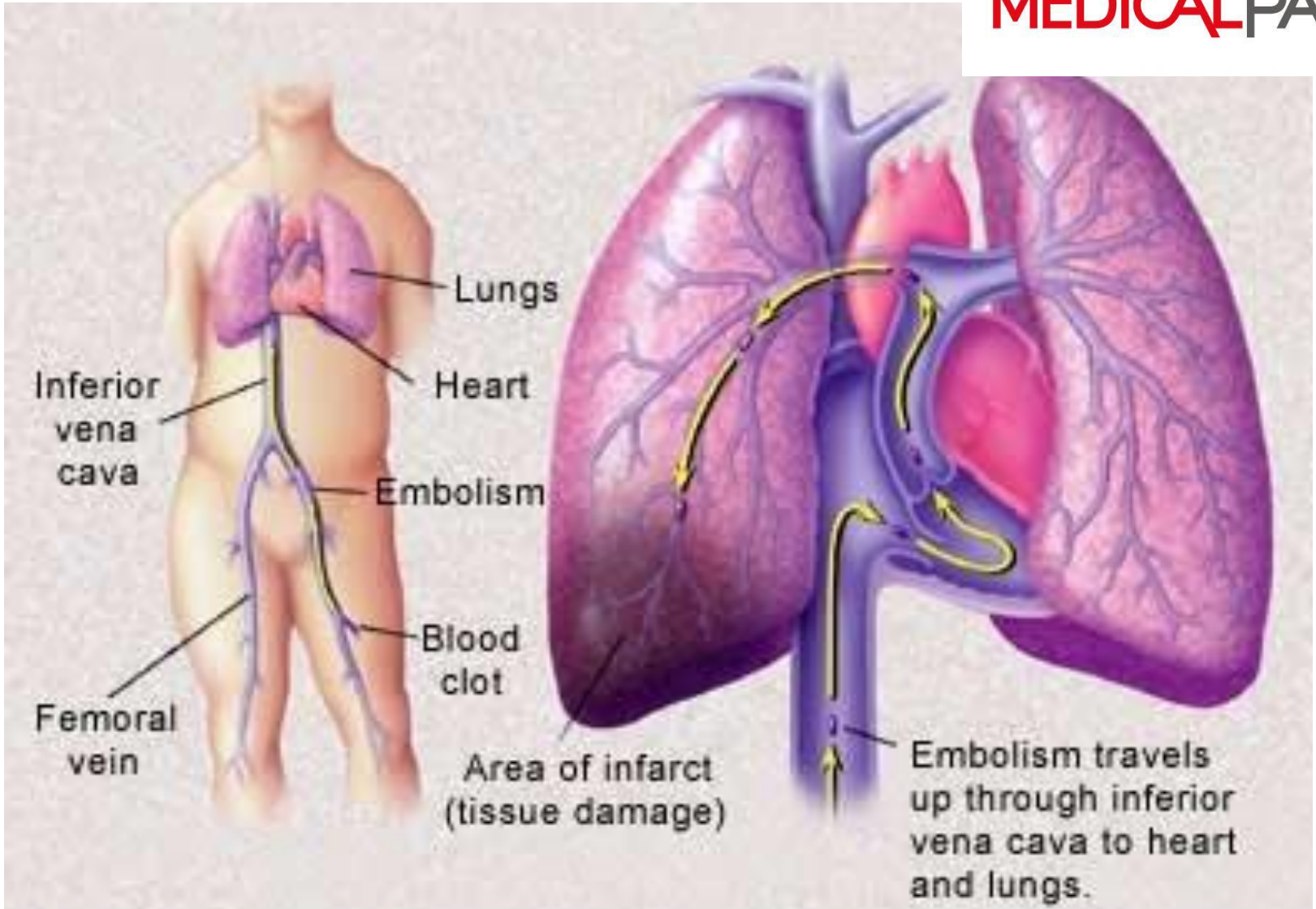
Pulmonary embolism in
main pulmonary artery



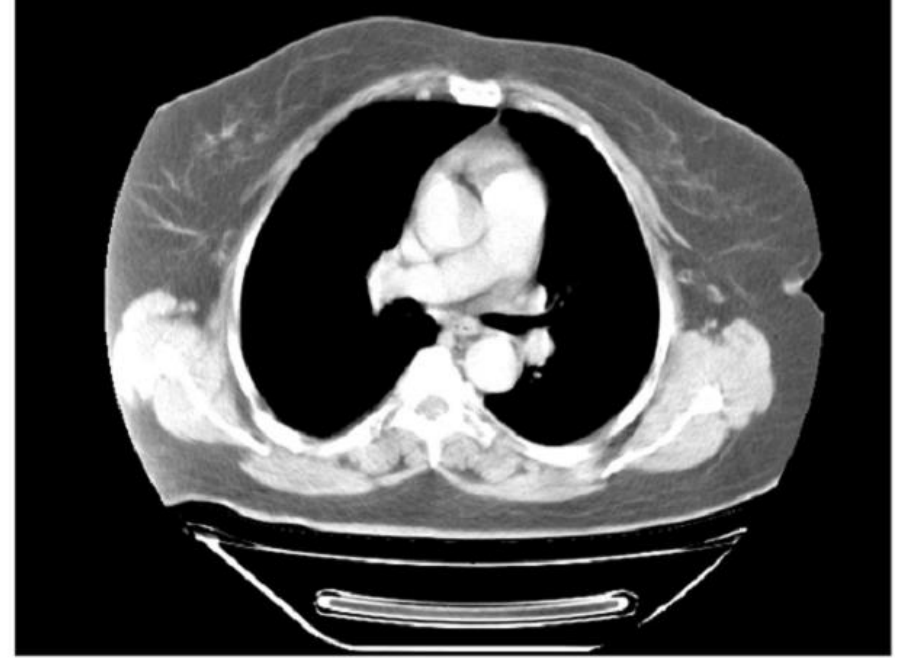
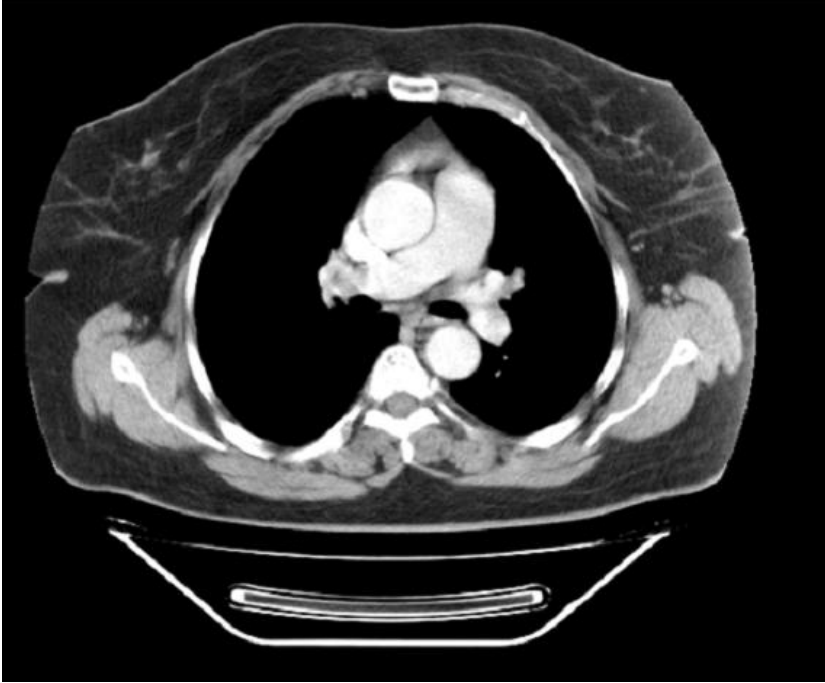
Antalya Kalp Hastanesi
Kalp ve Damar Cerrahisi Kliniđi



Antalya Kalp Hastanesi
Kalp ve Damar Cerrahisi Kliniđi



Antalya Kalp Hastanesi
Kalp ve Damar Cerrahisi Kliniği



Antalya Kalp Hastanesi
Kalp ve Damar Cerrahisi Kliniđi